Amsterdam UMC
University Medical Centers

Optical Coherence Tomography in urological surgery

its all optics & photonics

Daniel Martijn de Bruin

Dept of Biomedical Engineering & Physics
Dept of Urology

MEDICAL IMAGING MARKET

Optical
64%
$73 billion

Radiological
36%
$40 billion

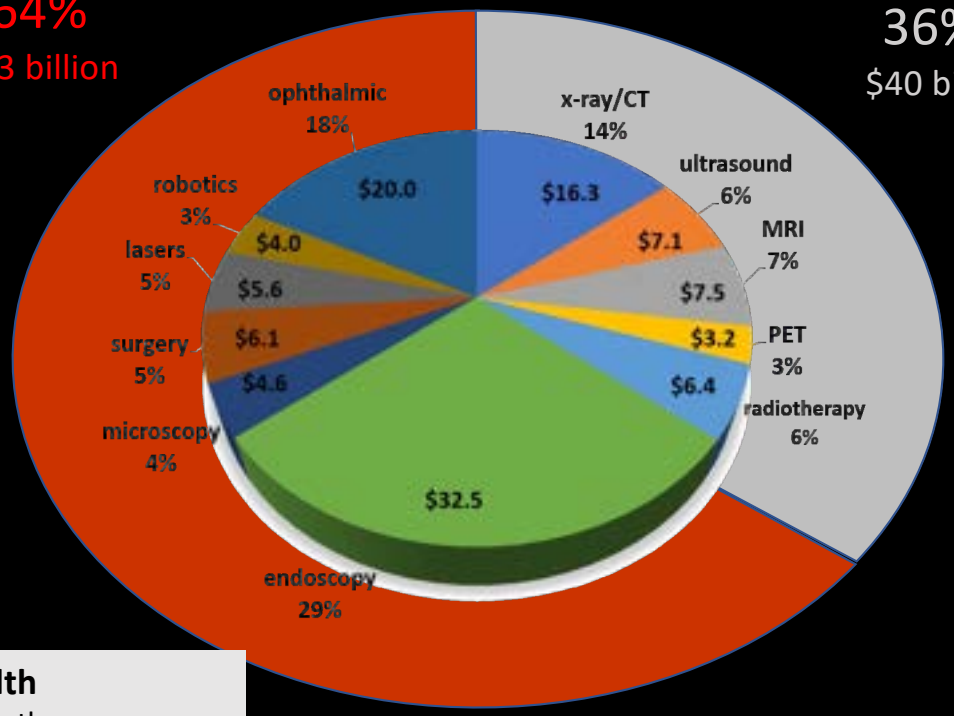

+ Mobile/Home Health
$20-40 billion + large growth

Pogue, SPIE Professional, January 2018

OPTICAL IMAGING @ AUMC

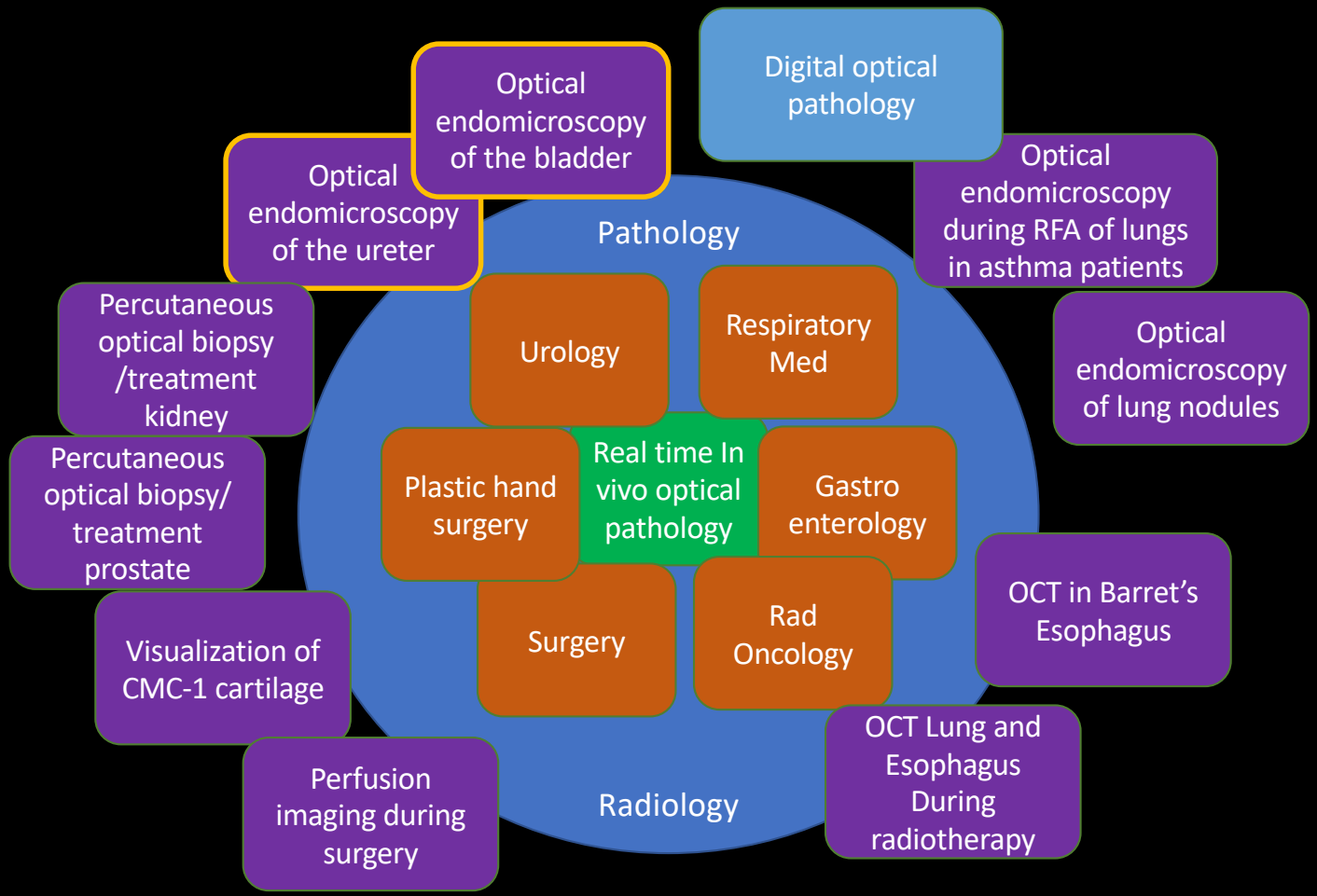

ENDOUROLOGY - ENDOUROLOGIST

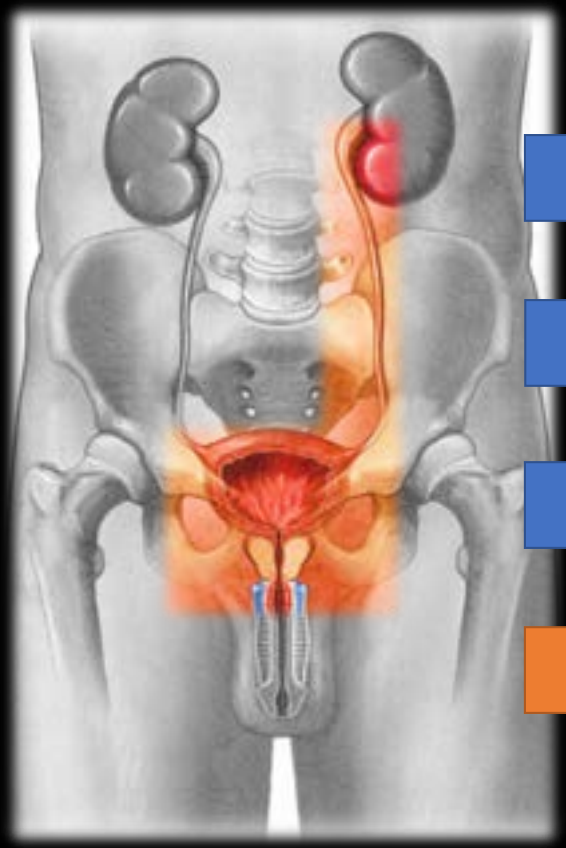

stones

enlarged benign prostate

stricture

cancer

UROTHELIAL CANCER

- **Urinary tract tumor 4th most common**
- **90-95% bladder /10-5 % ureter**
- **60% recurrence!!**
- **Lifetime follow-up!!**
- **Highest economic burden of all cancers!!**

Main causes of bladder cancer

Smoking and other tobacco use[1]

Past radiation exposure[1]

Chronic bladder inflammation[1]

Exposure to chemicals, especially at work[1]

Parasitic infections[1]

It is not always clear what causes bladder cancer, and some people can be diagnosed without having had exposure to any of the above listed causes.

1. Mayo Clinic. 2019. Bladder cancer. Available from: https://www.mayoclinic.org/diseases-conditions/bladder-cancer/symptoms-causes/syc-20356104

World Bladder Cancer Patient COALITION

CYSTOCOPY & URETERORENOSCOPY

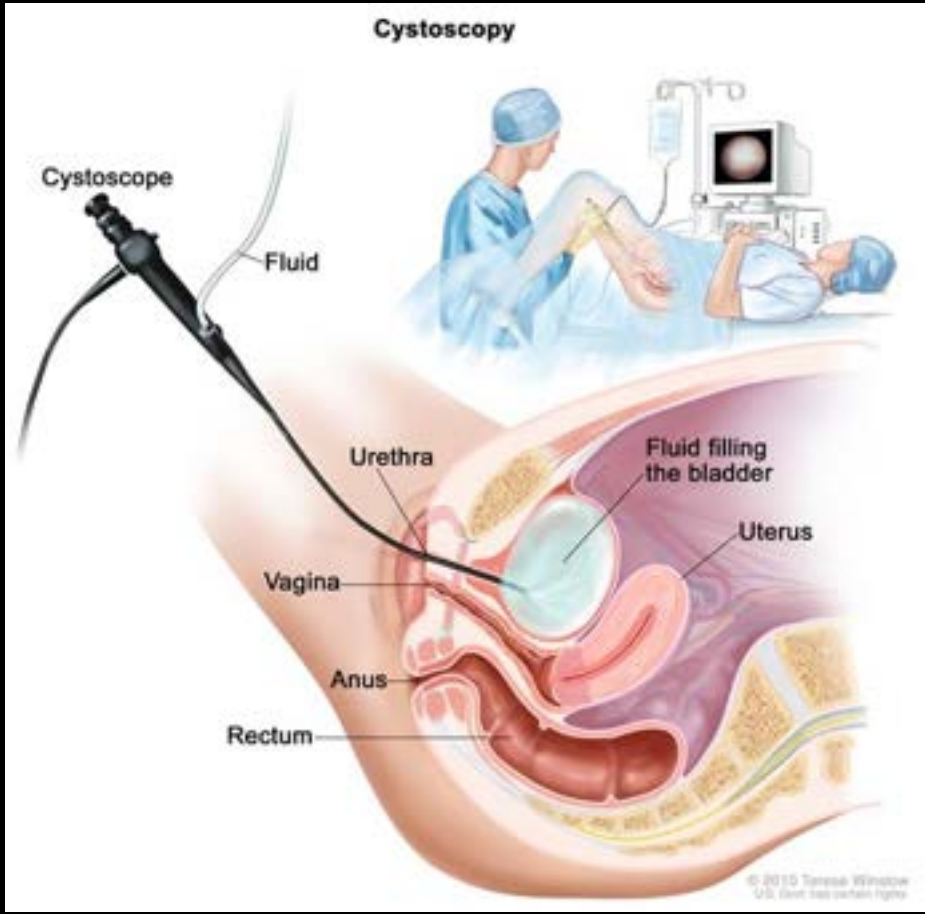

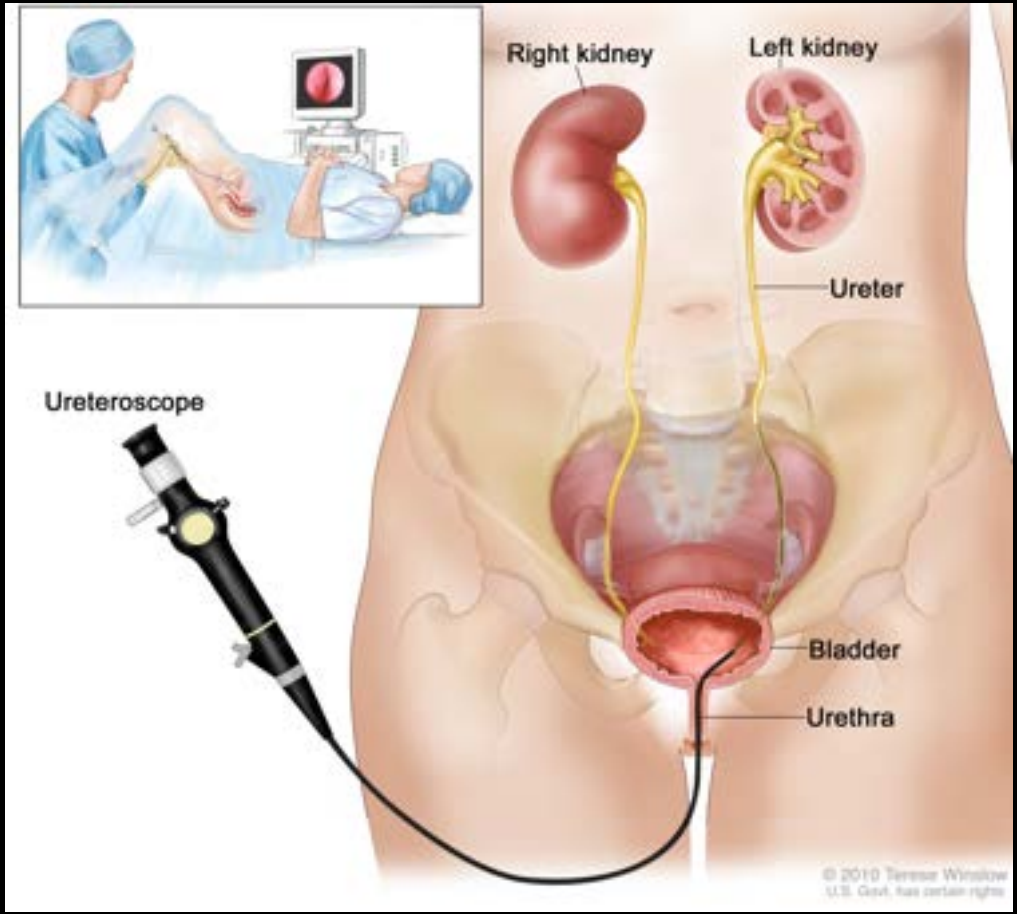

NARROW BAND IMAGING

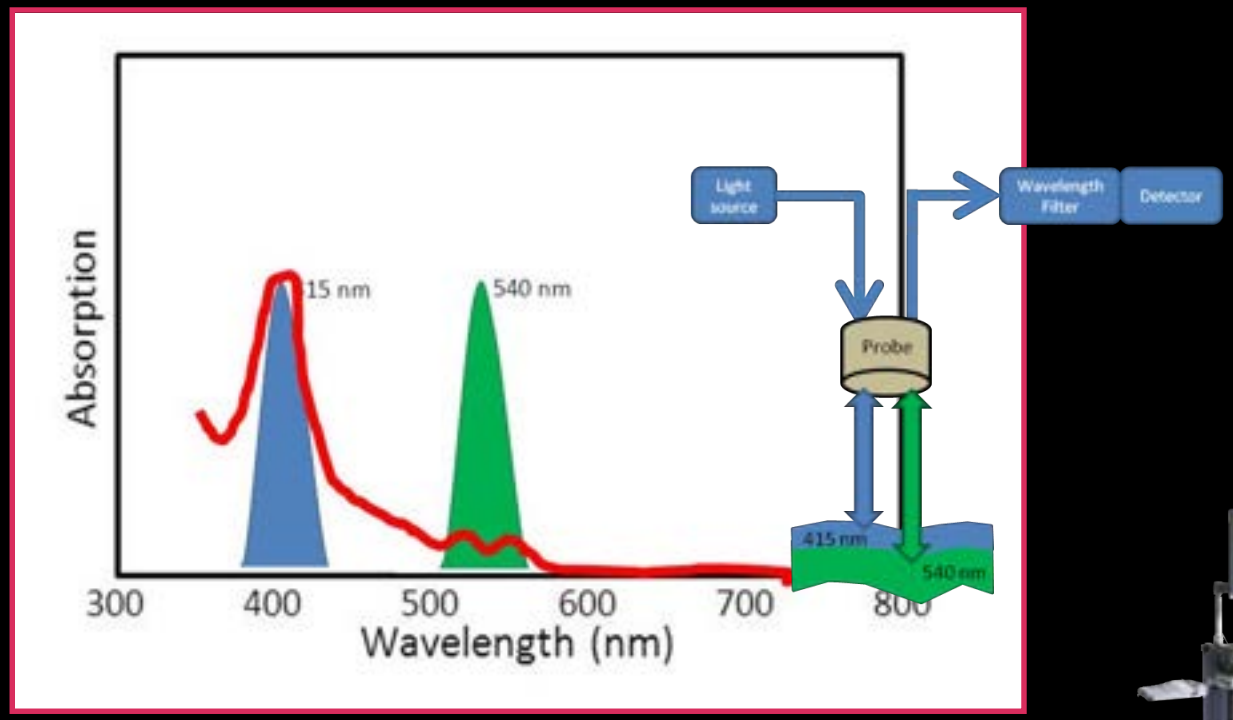

- Two colors (wavelengths) are used (415 & 540 nm)
- Both colors are absorbed by **Blood**
- Green light penetrates deeper, revealing deeper bloodvessels

STORZ PROFESIONAL IMAGING ENHANCMENT SYSTEM (SPIES)

Example in the bladder II

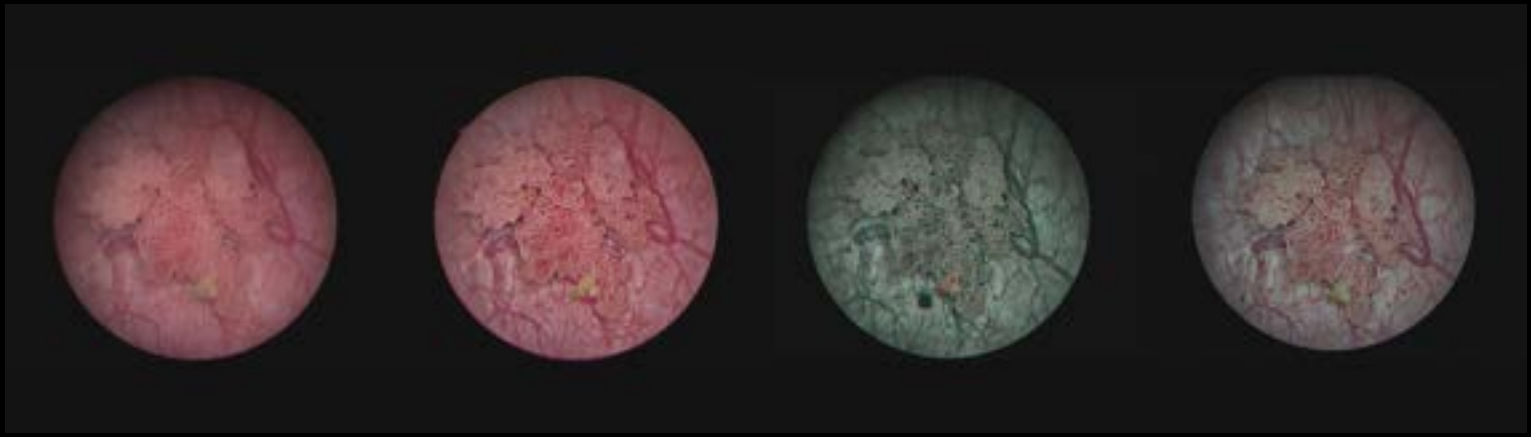

White light | Clara & Chroma | Spectra A | Spectra B

STORZ PROFESIONAL IMAGING ENHANCMENT SYSTEM (SPIES)

Example in the bladder I

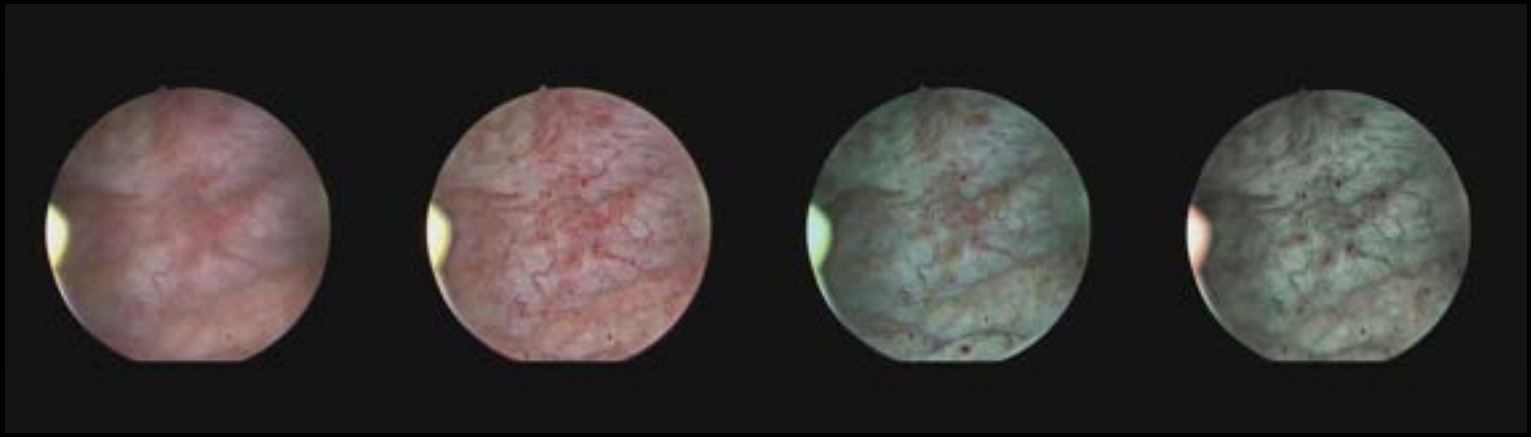

White light | Clara & Chroma | Spectra A | Spectra B

HARVESTING TISSUE

GRADING AND STAGING

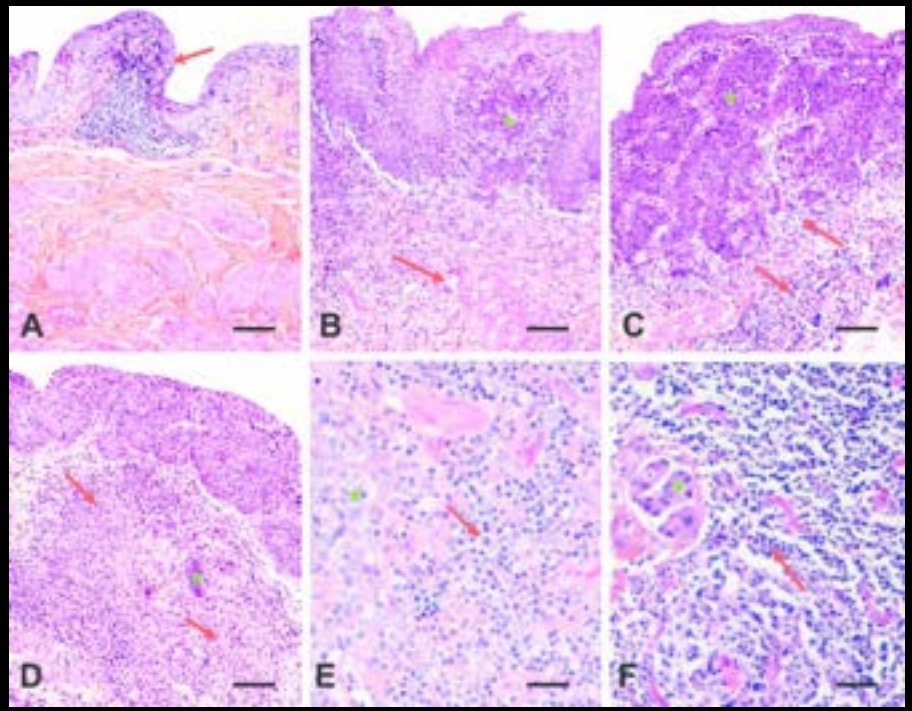

Grade: Aggressiveness

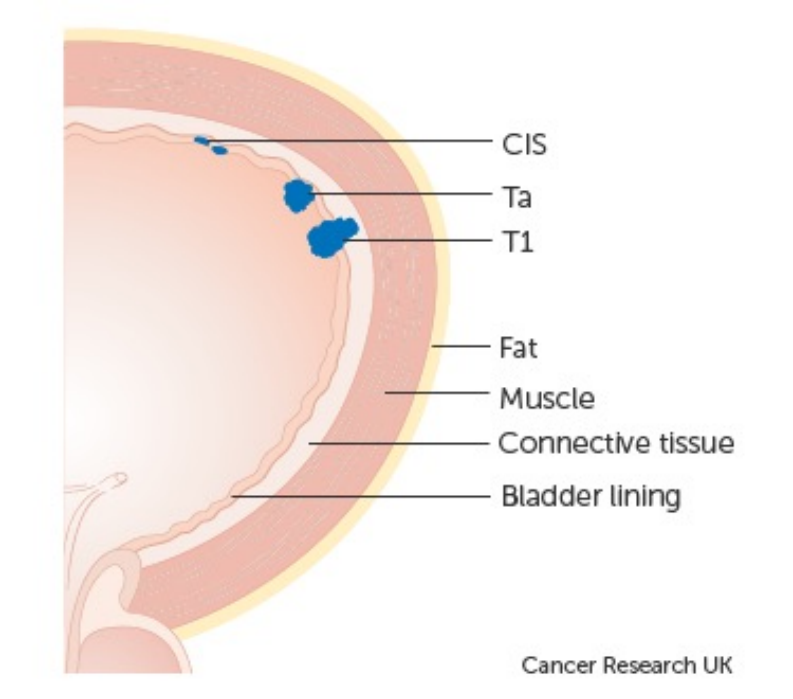

Stage: Invasiveness

TREATMENT OF UROTHELIAL CANCER

BLADDER CANCER: WHY OCT?

High Recurrence rates: **±30 % for LG after 5 years**
±80 % for HG after 5 years

High Interobserver variability by urologists (k= 0.62)

Red lesion detected at cystoscopy:
is this inflammation or CIS (highly malignant urothelial carcinoma)?

In case of expectative management of recurrences (watchful waiting):
no pathology is obtained

In case of laser treatment or fulguration of bladder tumors:
no pathology is obtained

CURRENT MANAGEMENT VS THE FUTURE

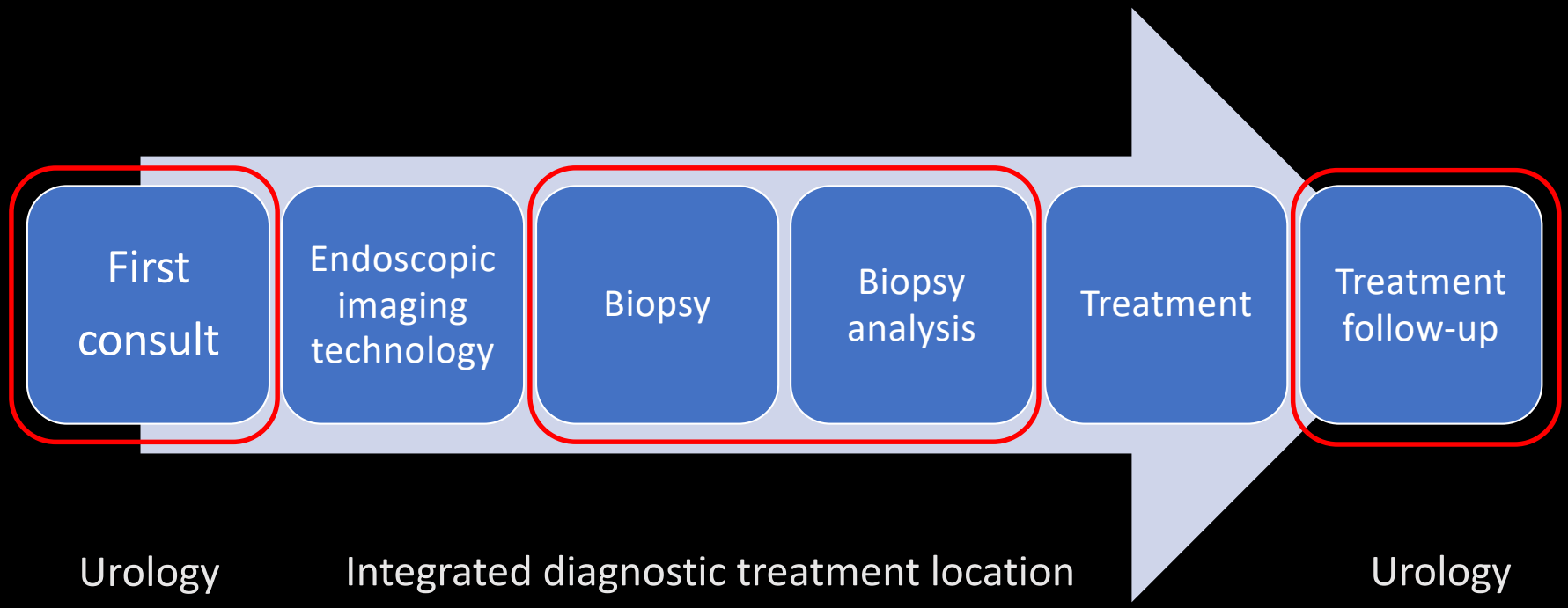

Urology outpatient clinic

Integrated diagnostic treatment location

Urology outpatient clinic

OPTICAL COHERENCE TOMOGRAPHY

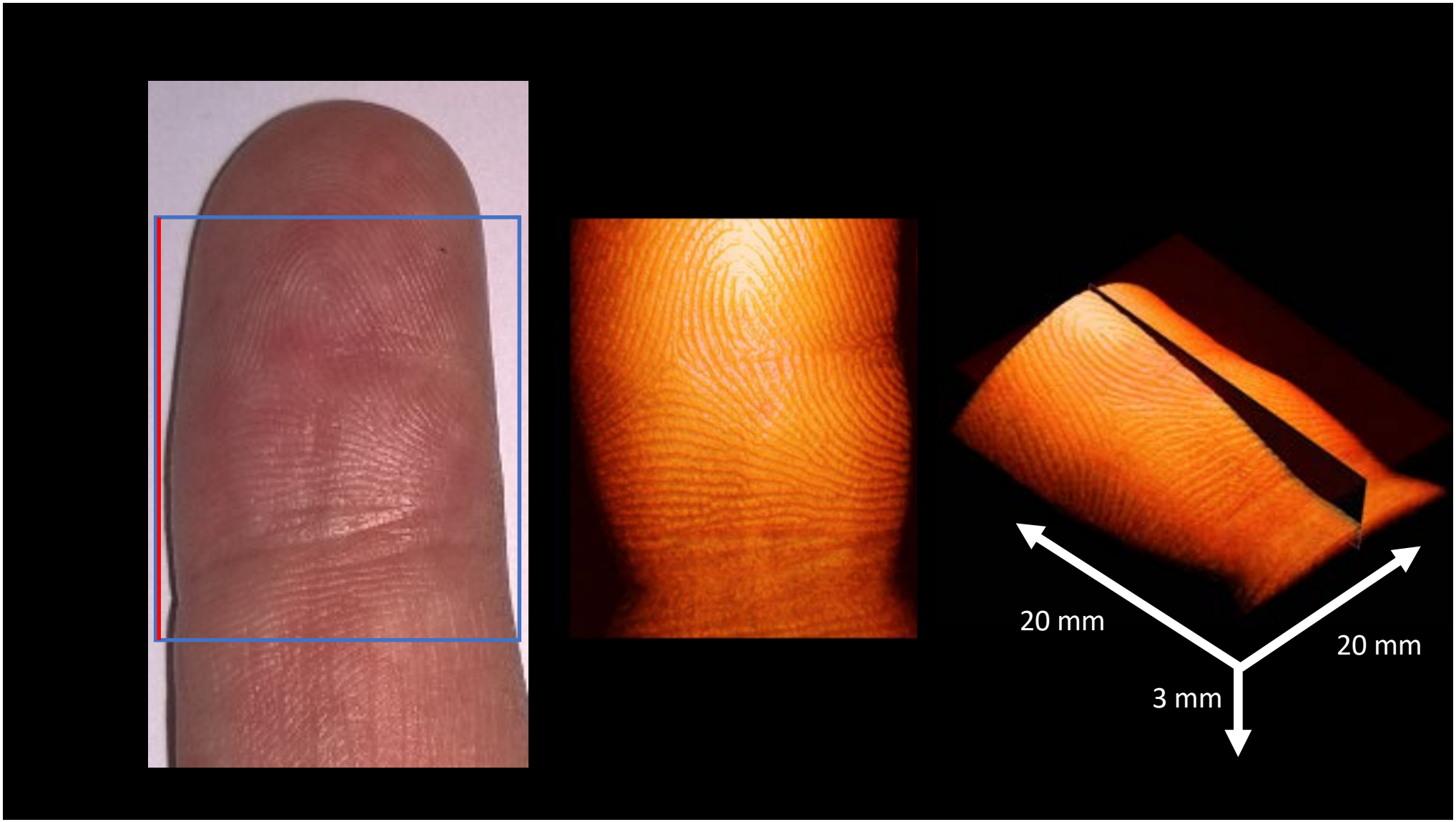
20 mm
20 mm
3 mm

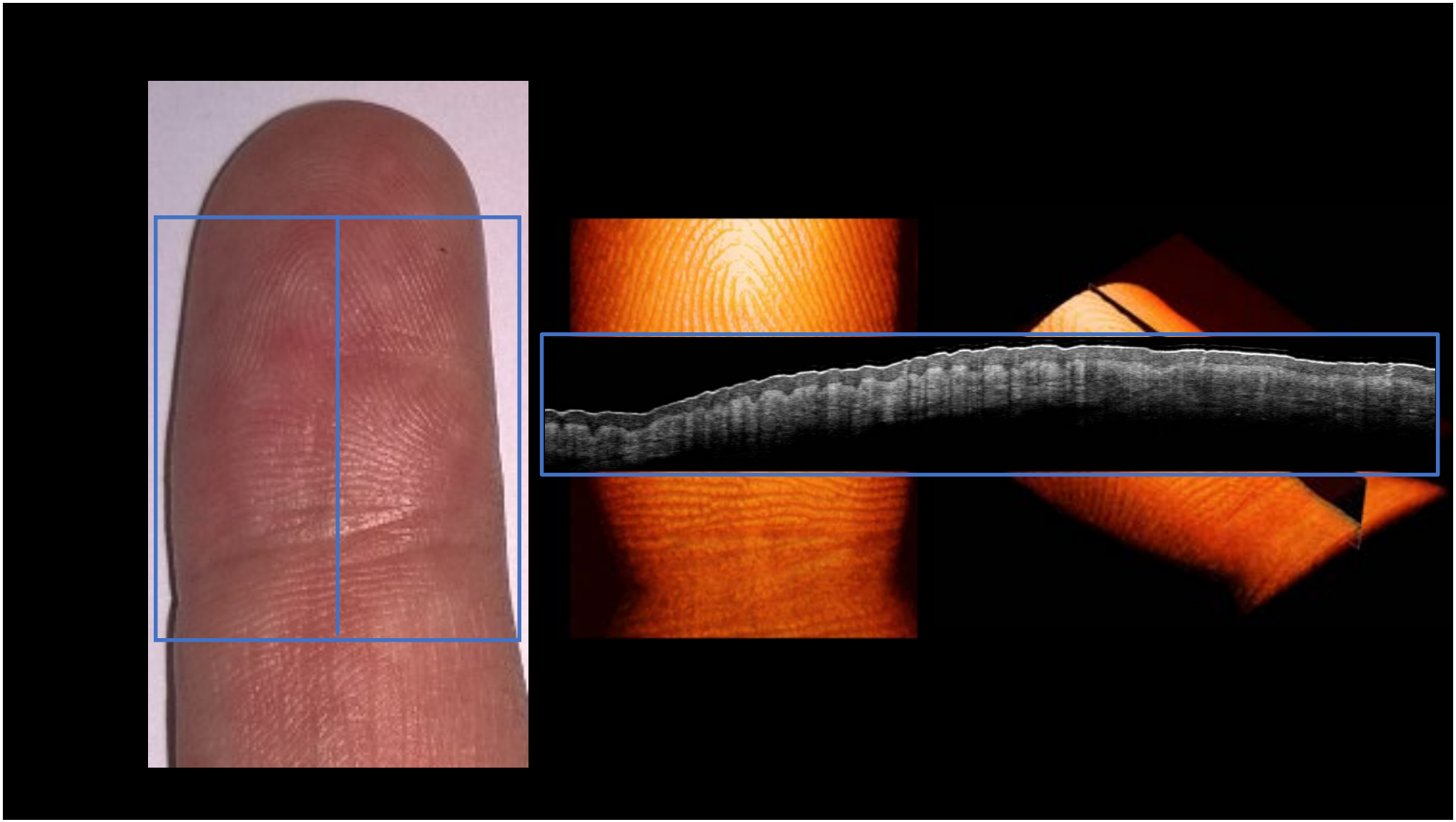

OCT IN UROLOGY: URETER

GOING ENDOSCOPIC

Development of small scale catheters

0.9 mm



100.000 times smaller
1600 times faster



OCT in Urology: Ureter

Bus etal, Jour of Uro, 2016

OCT in Urology: Ureter

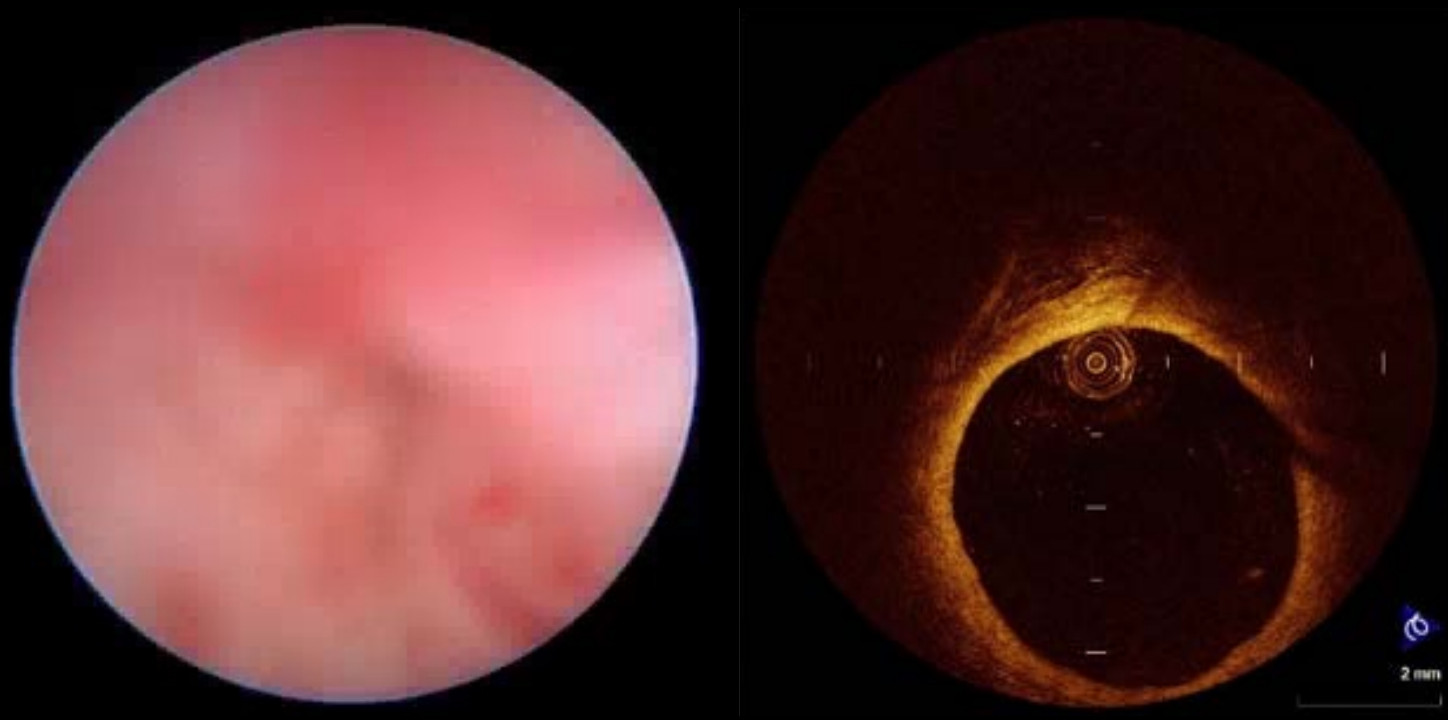

Bus etal, Jour of Uro, 2016

optical coherence tomography (OCT)

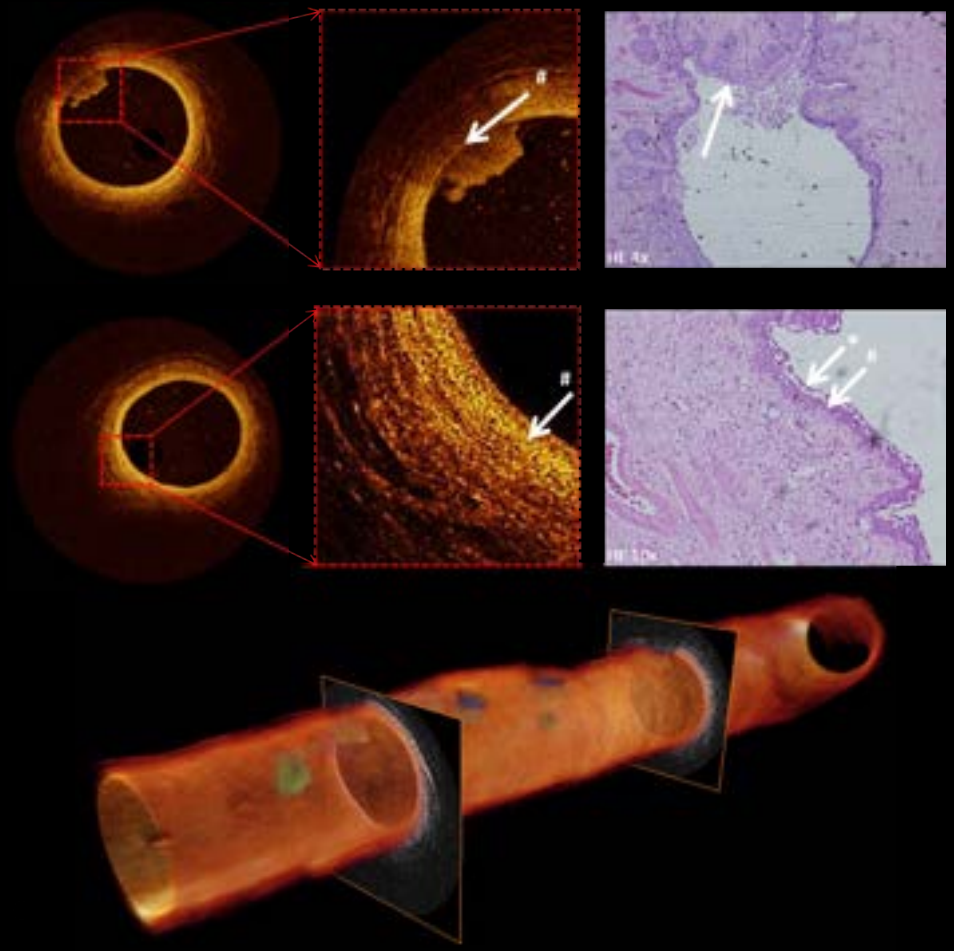

LOW STAGE: TA, G1-2

Bus etal, Jour of Uro, 2016

optical coherence tomography (OCT)

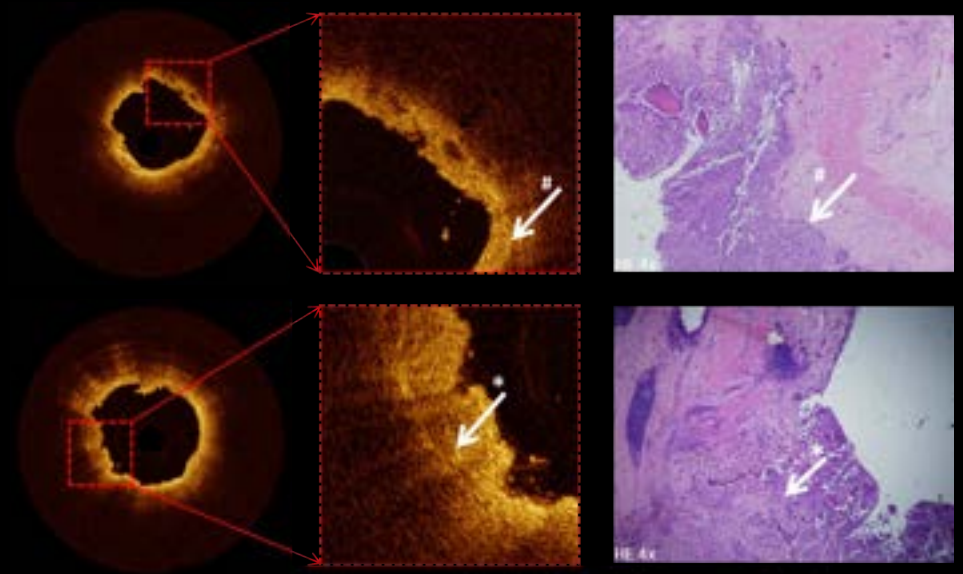

HIGH STAGE: T3, G3



Bus etal, Jour of Uro, 2016

QUANTIFCATION OF THE OCT SIGNAL: SCATTERING



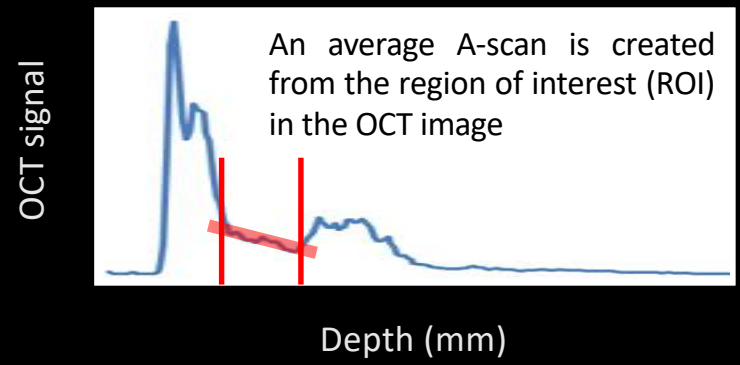

An average A-scan is created from the region of interest (ROI) in the OCT image

$$i_d \propto \left[e^{-2\mu_{oct} z} \right]^{\frac{1}{2}}$$

The **data** of the tissue part that is of interest can be fitted with Beers Law

RESULTS ON GRADING (n=35)

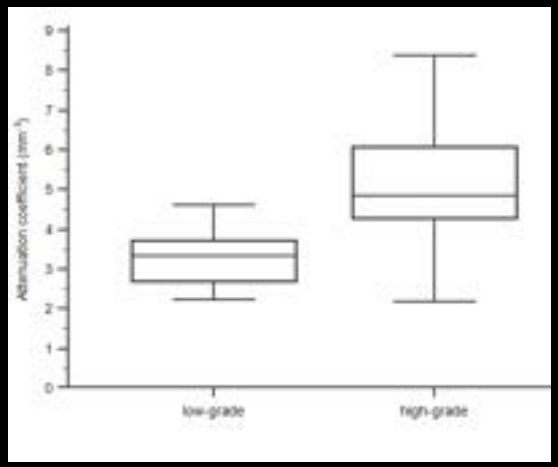

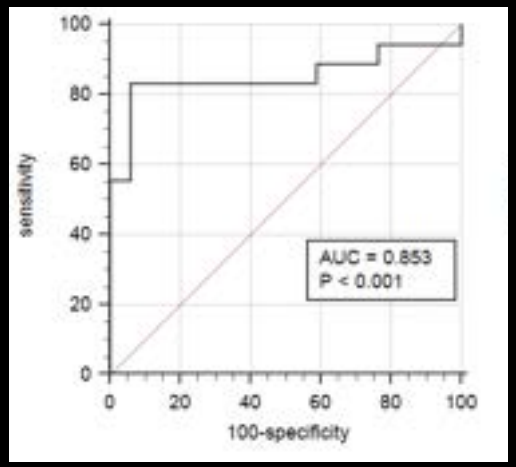

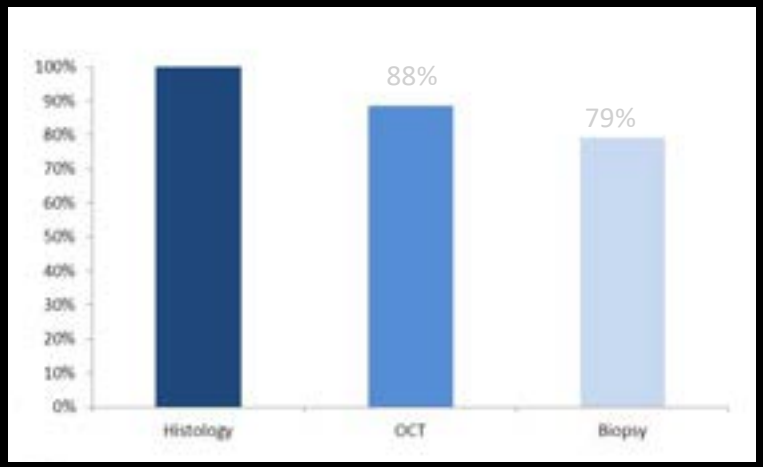

Freund etal, LISM, 2019

OCT END CLE IN THE EAU GUIDELINES

Optical coherence tomography and confocal laser endomicroscopy (Cellvizio©) have been used *in vivo* to evaluate tumour grade and/or for staging purposes, with a promising correlation with definitive histology in high-grade UTUC [68,69]. Recommendations are listed in Section 5.5.

FORWARD LOOKING PROBE DEVELOPMENT FOR THE BLADDER

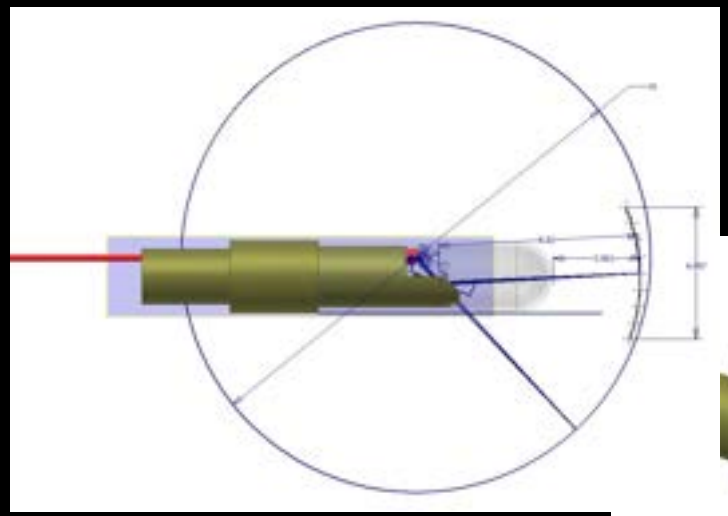

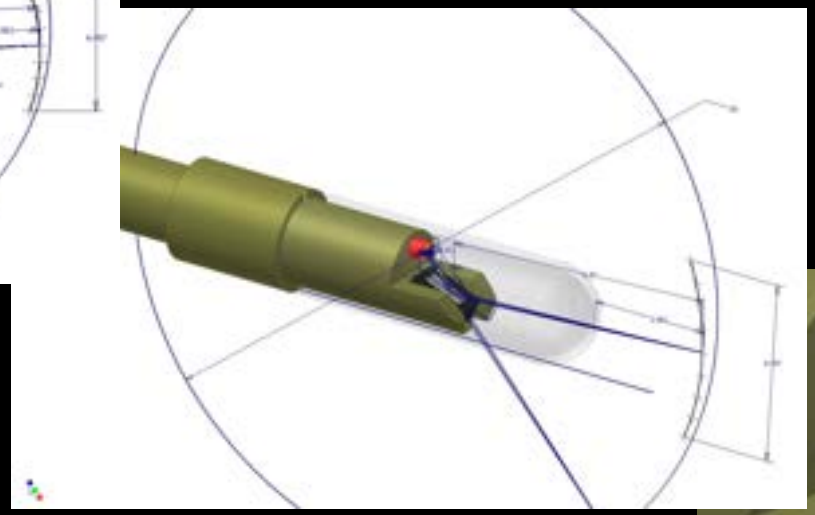

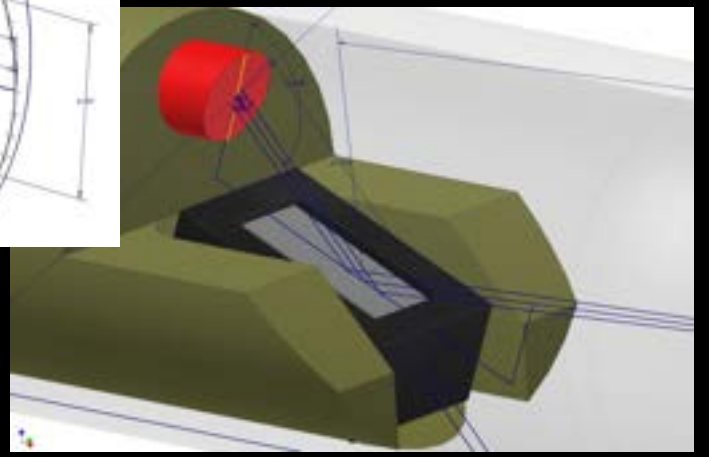

Scinvivo


Scinvivo catheter
Scinvivo patented MEMS mirror
this
is inside
Standard cystoscope with camera and lights
Scinvivo

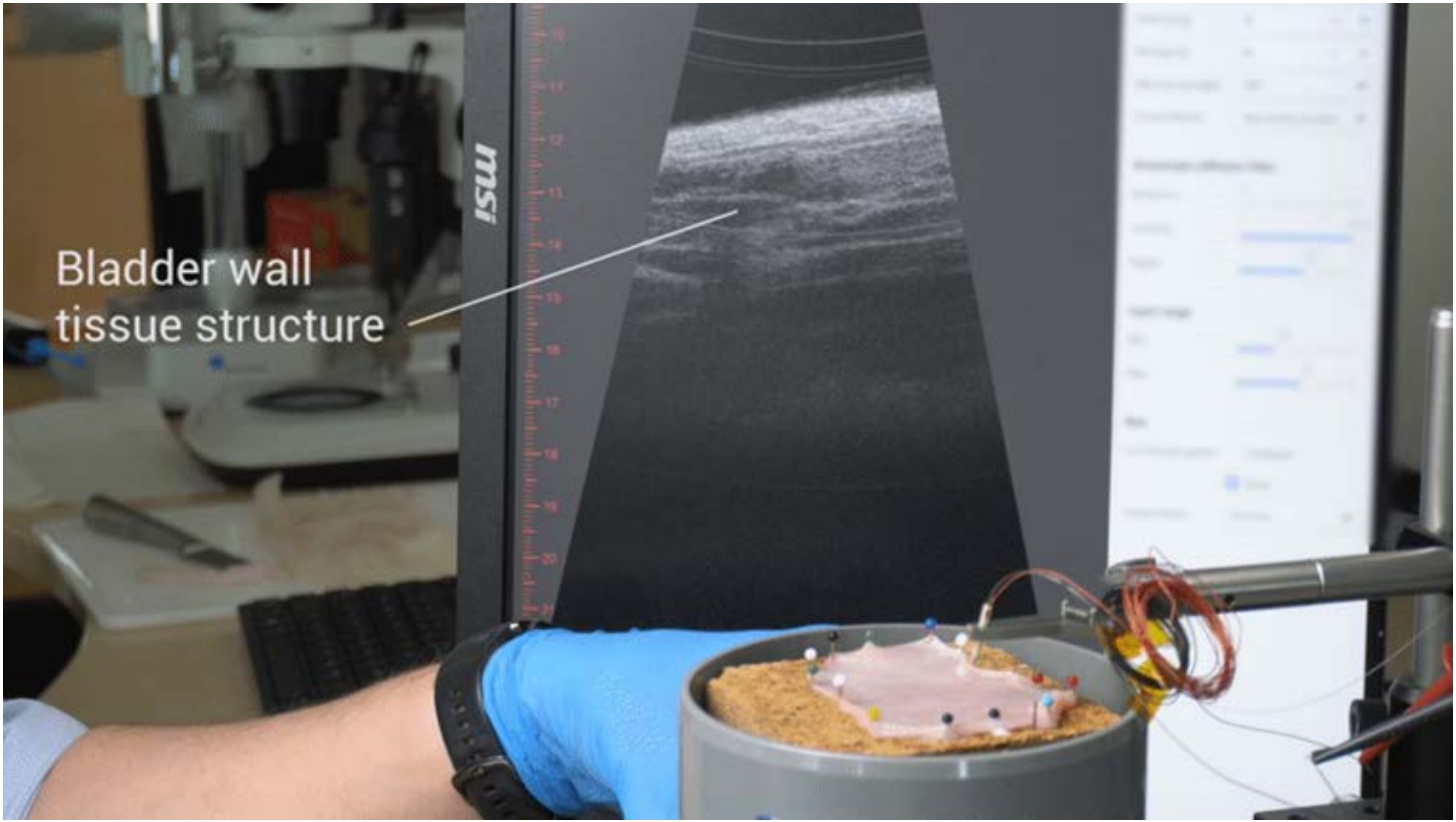
Bladder wall
tissue structure
msi

Conclusions

There is an urgent clinical need for real-time optical/photonic diagnostic technologies

Optical/photonic technologies will impact the current economic challenge

Optical Coherence Tomography can address this ‘need’

Catheter development for clinical OCT applications is crucial

OCT is the ideal platform to be interfaced with other optical modalities
(Fluorescence, Spectroscopy, Raman etc…)

ACKNOWLEDGEMENTS

luxflux
CURE FOR CANCER
Scinvivo
eurostars™
Amsterdam UMC
Universitair Medische Centra
NWO
Universitätsklinikum Tübingen